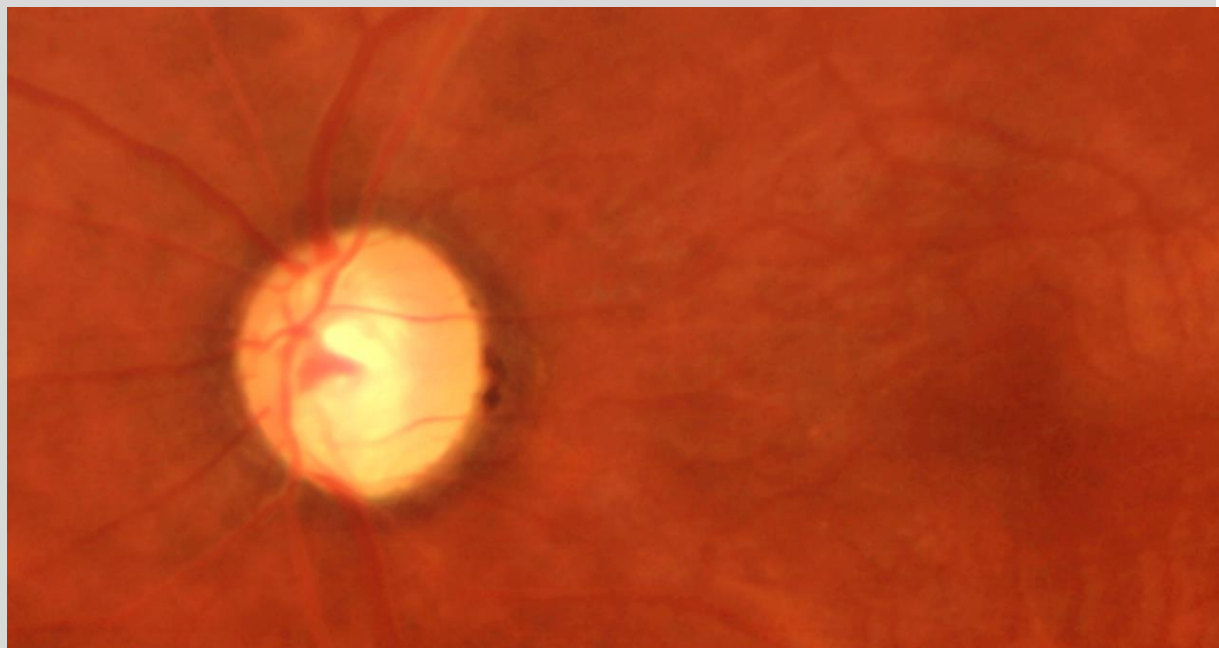




Glaucoma Society of India

GSI Newsletter

Issue No 3; September 2023



<https://www.glaucomasociety.in/>

Team Newsletter



Dr Julie Pegu



Dr Paaraj Dave



Dr Parivadhini A



Dr Shahinur Tayab



Dr Swati Upadhyaya

Editorial



Dear seniors, friends, and colleagues
Greetings from the editorial team of the GSI newsletter. The third issue of the e-newsletter is on your screen, though after a long gap. Secretary GSI, Dr Manav Deep Singh, was very keen to revive the e-newsletter, and President, Dr Barun Nayak, gave unconditional support for this.

This issue of the e-newsletter focuses on minimally invasive glaucoma surgery (MIGS). In our column "*Practice Point*," the opinion of India's glaucoma surgeons on MIGS is highlighted in the form of a panel discussion. The experts have shared their views on clinical and other aspects of MIGS. Also, try your knowledge of MIGS at the "*Glaucoma Crossroad*," which is regularly contributed by Dr Puravi Bhagat.

I would request that you share opportunities for glaucoma training available in your hospital or institute so that we can include them in forthcoming issues of the e-newsletter.

The annual conference of the Glaucoma Society of India is around the corner. I hope you will have an enriching experience in Pune.

Happy reading, and as always, we welcome suggestions for improvement of the GSI e-newsletter.

Dr Parveen Rewri

Editor

gsinewseditor@gmail.com

Disclaimer

The aim of the GSI e-newsletter is to provide a platform for ophthalmologists to interact and learn about glaucoma from experienced specialists and to promote the exchange of ideas, news, views, and updates. Its content does not represent the official opinion of GSI, and all views expressed are those of individual authors.

President's message



Dear members,

Greetings from the desk of the President of GSI.

First, I congratulate Dr Parveen Rewri, the editor, and his entire editorial team for bringing out this e-newsletter. It contains a variety of useful material and information, which is the culmination of the hard work done by his team.

Our annual conference, GlaucoPune2023, is only a couple of weeks away. The scientific program with confirmed faculty and their topic was ready two months before the conference, and it was put up on the website for anyone to see. It contains instruction courses, plenary sessions, and wet labs. I can assure you that the scientific content is going to be of high standard, and there will be some useful knowledge to take back home for all the delegates. *Meet the Masters* is the new introduction this year, wherein one expert will interact with just six delegates for one hour so that their doubts can be clarified on a one-to-one basis. Please book your slot early to avoid disappointment.

It will be a mega event with around 800 delegates. The LOC with the central team is leaving no stone unturned to make this conference useful, comfortable, and enjoyable. Please register for the conference at the earliest if you have not done so far.

With kind regards,

Barun Kumar Nayak
President, GSI

Secretary's message



We at GSI are excited to bring you this first newsletter of the session 2021-23. We started a scientific discussion group immediately after taking over the office, and we started this e-newsletter under the leadership of a well-known academician and professor, Dr Parveen Rewri. I congratulate him and his editorial team.

I am thankful to the members of the executive body, advisory board, and zonal members for various academic and non-academic activities. To share progress and the process of society, zonal WhatsApp groups have been created.

I am extremely thankful to members for participating in glaucoma awareness activities, especially Dr Sachin Dharwarkar, who was instrumental in bringing out video clips during *World Glaucoma Week 2023*.

I am thankful to Dr B K Nayak, Dr Tanuj, Dada, and Dr L Vijaya, who helped us get a refund of the registration fee for the members of GSI who could not attend the World Congress due to visa-related issues.

The work on the amendment of the constitution of the Glaucoma Society of India is in full swing to achieve a statutory-compliant set of bylaws for the society.


For the 32nd annual conference, the executive body and LOC Pune started working on the very second day. I am grateful to the faculty, trade, delegates, and LOC, who have given enthusiastic responses. A great conference is anticipated, and all of you are invited.

Long live GSI.

Jai Hind!"

Dr Manav Deep Singh
Secretary, GSI

Practice Point



Minimally Invasive Glaucoma Surgery

Minimally Invasive Glaucoma Surgery, or MIGS refers to a range of implants, devices, or techniques that aim to reduce intraocular pressure (IOP) through an approach that usually spares or minimally affects the conjunctiva. These procedures are evolving, and our understanding of their optimal use for long-term control of IOP has improved in the last couple of years. In India, these procedures are still not being performed commonly. Our practice point in this issue of the *GSI Newsletter* focuses on various basic, clinical, and logistic aspects of MIGS. In this panel discussion, we are presenting excerpts from the discussion by experts: Dr Lingam Vijaya (Sankara Nethralya, Chennai), Dr Sirisha Senthil (LV Prasad Institute, Hyderabad), Dr Suneeta Dubey (Shroff Charity Eye Hospital, Delhi), Dr Vanita Pathak Ray (Centre for Sight, Hyderabad), and Dr Ganesh Venkataraman (Aravind Eye Hospital, Coimbatore).

Newsletter team (NT): Can you give us a brief overview of the current status of minimally invasive glaucoma surgery (MIGS) in glaucoma management?

Dr Ganesh Venkataraman (GVR): MIGS have burst into the glaucoma armamentarium with main advantage of preservation of conjunctiva while achieving IOP lowering. Apart from this, the procedure is fast with quick recovery time, lesser postoperative visits and manipulation during those visits, good safety profile and cosmetically acceptable. With these advantages there is some demerit to MIGS which their applicability in mild to moderate glaucoma and their usefulness only in open angle glaucoma.

Dr Lingam Vijaya (LV): In the spectrum of glaucoma treatment MIGS comes in between medication/SLT and conventional glaucoma surgery such as trabeculectomy or Glaucoma drainage devices (GDD). These are meant for mild to moderate open angle glaucomas. They have modest efficacy in terms of IOP control.

Dr Sirisha Senthil (SS): The term MIGS is applied to a wide range of implants, devices, and techniques that lower the IOP with lesser surgical risk, cause minimal or no trauma to the conjunctiva, and have faster visual recovery and good safety profile. The indication of MIGS is mild to moderate open angle glaucoma, both primary and secondary, that require two or more IOP-lowering drugs. AGM, mild AGM allergy.

Dr Suneeta Dubey (SD): MIGS has been developed as safer and less traumatic surgical intervention for patients with glaucoma to bridge the gap between pharmacotherapy & traditional invasive glaucoma surgeries. There is a strong rationale for wider use of MIGS, early in the treatment sequence, in patients with mild to moderate disease at high risk of suboptimal IOP control with medical therapy, or in patients who need high-dose combination therapy to adequately lower IOP with or without cataract surgery.

Dr Vanita Pathak Ray (VPR): The term is applied to a wide range of implants, devices, and techniques, that lower intraocular pressure (IOP) with much reduced surgical risk, in a less invasive manner,

when compared to the more established bleb-forming sub-conjunctival drainage procedures - trabeculectomy and GDD. Currently available MIGS either target the physiological outflow pathways of trabecular meshwork and Schlemm's canal or aqueous formation. Former include i-Stent, Hydrus, OMNI, Trabectome, Kahook Dual Blade (KDB) glide, Gonioscopy Assisted Transluminal Trabeculotomy (GATT), and Bent Ab-interno Needle Goniectomy (BANG). Example for those tackling aqueous inflow is endoscopic cyclophotocoagulation (ECP).

NT: What is your preferred MIGS and why?

GVR: Although not a true MIGS, the procedure of choice for me at present is Gonioscopy assisted transluminal trabeculotomy (GATT).

LV: We have limited devices available in India and with time we will have access for many more. We have taken a conscious decision to have a conservative approach in offering this mode of treatment. At present at our institute, we are doing Kahook Dual Blade (KDB) and i-stent inject, looking forwards for Hydrus.

SS: Prolene suture Gonioscopy assisted transluminal trabeculotomy (GATT) is our preferred MIGS as it is a cost-effective. In our experience it has shown good IOP control, increased safety profile, less post-operative visits. Hyphema is the most common complication noticed which resolves over a period except in rare instances (1:200 may need wash). We have been able to perform this technique with good outcomes even in eyes with prior failed glaucoma filtering surgeries including trabeculectomy and tube in open angle glaucoma.

SD: After performing several MIGS procedures in my clinical practice, I would like to stress that these procedures are not one size fits all. I find KDB a good option because of ease of its use, cost effectiveness & IOP lowering effect. However, I tend to individualize treatment depending on the type & severity of glaucoma.

VPR: Overall options available is still quite limited in India. Management is tailored to suit the individual not only clinically but also considering expectations related to the outcomes and affordability of the procedure or device - under these circumstances, there cannot be a "preferred" MIGS. Each should be considered with due deliberation and offered in individual situations, for distinct indications, in

patients with disparate clinical pictures, in order to achieve the desirable outcomes.

NT: What are the various factors to be considered while choosing a MIGS? or, in other words, how to decide which MIGS to use?

GVR: MIGS are ideally suited for mild to moderate glaucoma. MIGS work best when the eyes have not been medicated for lengthy periods or very intensely. Accelerated control of glaucoma is also an indication that MIGS may not work.

LV: Aim of the two MIGS we are using is restoring flow through Schlemm's canal into the collector channels present in supra-nasal and temporal quadrant. So, collector channels should be functioning for it to be effective. In view of this they will not work for advanced open angle glaucomas. Broadly indications are pre-operative IOP up to 30 mmHg with medications, target IOP up to 15 mmHg, eyes with ocular surface disorders (OSD) due to multiple medications, patients who have trouble in administering medications. MIGS are usually done along with cataract surgery.

SS: All the MIGS are indicated in open angle glaucoma. Other factors one should consider include target IOP, the cost of device and surgery, surgeons experience or comfort with the procedure. MIGS patients may need one or more antiglaucoma drops. We would avoid MIGS in someone with who has severe allergy to IOP-lowering drugs or those who need low target IOP with very advanced damage.

SD: I-stent should only be used in OAG patients, while GATT, BANG & KDB can be done in ACG patients also with or without synecheolysis. Bearing in mind the learning curve, from the easiest to hardest modality – i-stent> KDB> GATT; procedural cost – GATT<KDB<i-stent.

VPR: There are no published guidelines on how to decide which MIGS is to be used. I have devised my own guidelines for self-usage based on my cumulative experience while performing MIGS over half a decade. Though I usually offer MIGS when I am contemplating cataract surgery in glaucoma patients, but I also do a standalone MIGS in phakic and pseudophakic eyes. I will restrict my options to those devices and procedures that are available in India. The choice in open angle (even those where angle opens post laser PI) in India are – i-Stent, i-Stent Inject, KDB glide, BANG, Trabectome, GATT

and ECP. Trabectome is not widely available (I, too, do not have access to it) but can be used in all those conditions that KDB glide and BANG are contemplated. The option available in synechial angle closure is ECP.

NT: Is there a way to decide if the collector channels are functional? Do you do a pre-test?

GVR: My criteria for offering angular MIGS are recent diagnosis and no prior extensive medication (IOP control should be controlled with a maximum of 3 eyedrops). If he requires a 4th eyedrop I would offer conventional glaucoma procedure or canaloplasty to the patient.

LV: Difficult to assess and I do not do.

SS: We can perform trypan blue dye test to help delineate the patent episcleral and intrascleral outflow system. Blanching test can be performed by injecting a jet of saline to see the blanching in the episcleral vessels, performed after completion of MIGS procedure.

SD: Aqueous angiography can be performed prior to the procedure to check patency of collector channels; however, it may not be feasible to do so.

VRP: Provocative pre-surgery gonioscopy testing can suggest the location of unobstructed collector channels and aqueous veins. Blood reflux from collector channels into Schlemm's canal was semi-quantitatively evaluated - the quality of reflux and episcleral venous egress may both be predictive of the level of IOP after surgery. Based on this I target the areas of focal blood reflux as sites for Schlemm's canal device implantation or trabecular meshwork incision. However, there is no definitive pre-test available.

NT: Which patient is your best candidate for MIGS? What keeps it above traditional methods?

GVR: My best patients are those who have juvenile open angle glaucoma or primary open angle glaucoma, have good visual acuity and normal appearing angles with age-appropriate pigmentation of the trabecular meshwork.

LV: One with mild to moderate open angle glaucoma and going for cataract surgery.

SS: As I mentioned before, patients who have open angles with mild to moderate glaucoma who are on two or more medications needing a cataract

surgery, having allergy to IOP-lowering drugs and where conjunctival based procedures are difficult to perform, failed previous trabeculectomy or tube with conjunctival scarring, high IOP with either no disc damage or early damage.

SD: Best candidate would be patients with mild to moderate OAG, pigmentary pseudo exfoliation glaucoma and angle closure glaucoma after peripheral iridectomy with open angles along with cataract surgery.

VRP: A significant proportion of ocular hypertensives or early glaucoma patients, mild-to-moderates, determined predominantly based on mean deviation (MD) on visual fields benefit from MIGS procedures. Such patients who are on multiple anti-glaucoma medications (AGM) and are due to undergo cataract surgery, may be offered MIGS along with it, rather than the need to wait for the disease to progress or become uncontrollable and/or advanced.

NT: How does angle status affect MIGS procedure?

GVR: Angle status and corneal clarity are very important in my experience. There should not be any anterior iris insertion. Angle closure of any grade is a strict contraindication for beginners. The pigmentation of the trabecular meshwork is a good sign to identify the site of MIGS surgery.

LV: Obviously angle should be open and with some pigmentation of trabecular meshwork.

SS: MIGS devices which utilize the conventional aqueous outflow pathway requires open angles. The techniques involve (Stenting, dilatation, cutting or ablation) of the TM to provide access to or directly opening the Schlemm's canal. Even in cases the angle is closed in few quadrants these can be attempted in the area of open angle and can be partially successful in IOP control which may help decrease some burden of AGM or avoid a major surgical intervention.

SD: For a novice surgeon, the angle status is of utmost importance. For initial few cases, only OAG patients should be chosen whereas chronic angle closure glaucoma with peripheral anterior synechiae & NVG should be avoided.

VRP: Most devices and procedures are suitable for open angles; this includes those which open after laser peripheral iridotomy. However, several surgeons combine it with gonio-synecheolysis when

operating in synechial angle closure. Endoscopic cyclophotocoagulation is completely independent of angle status, can be used in eyes with angle closure.

NT: Is IOP lowering with MIGS comparable and cost-effective to trabeculectomy?

GVR: Comparing the cost of MIGS to trabeculectomy will not be possible until we consider in the cost of MIGS device and investment involved in other instrumentation like tiltable microscope, surgical gonioscope, other surgical instruments, and sutures. Also, to consider cost of postoperative visits, and the cost of re-surgery if the primary surgery fails.

LV: It is very important to understand MIGS is not replacement for trabeculectomy, it is meant for mild to moderate glaucoma and as I said before, in the spectrum of treatment it comes between medication/laser and standard glaucoma surgeries.

SS: Some of the MIGS have comparable results in certain subset of patients. When performed well, trabeculectomy (with antifibrotics) provides better and long term IOP control. MIGS can be performed as a primary procedure only in mild to moderate open angle glaucoma who are on 2 or more medications but trabeculectomy is preferred in advanced glaucoma and in angle closure glaucoma.

SD: There is limited available evidence on the cost effectiveness of MIGS, & therefore it remains unclear whether the cost of using MIGS is outweighed by cost savings through decreased medication burden & need for further intervention.

VRP: The efficacy of most MIGS procedures is often modest compared to more invasive glaucoma surgeries such as trabeculectomy with or without mitomycin C or even GDD. This compromise in efficacy is balanced by an ultra-low risk profile.

NT: Can MIGS lower pressure further when done after a trabeculectomy with MMC?

GVR: If trabeculectomy was done for angle closure disease, it is best to avoid MIGS in such eyes. In case of open angle glaucoma, I would prefer a GATT procedure but only if I know it has been an uneventful trabeculectomy and no postoperative complications has occurred apart from bleb failure.

LV: Does it mean failed trabeculectomy? I do not think it is a good option.

SS: Yes, this has been our initial experience when we started MIGS in eyes with failed one or two trabeculectomies or tubes.

SD: Studies have shown MIGS can lower IOP in patents with failed trabeculectomy with MMC and GDD as the collector channels do not atrophy completely.

VRP: Yes, there is some evidence that MIGS can lower IOP if trabeculectomy with mitomycin C fails to achieve target IOP even with the addition of AGM.

NT: What types of complications should one expect following MIGS?

GVR: Hyphema, incomplete canalulation in canal-based surgeries, IOP spike, Descemet's membrane detachment, lens touch and cataract formation, and Iridodialysis. Other complications which may happen are cyclodialysis, device obstruction with peripheral anterior synechiae, peripheral anterior synechiae, device dislodgement/ malposition in implantable device, medically uncontrolled glaucoma leading to additional glaucoma surgery, pan scleritis, toxic anterior segment syndrome, suprachoroidal haemorrhage, and loss of vision in advanced glaucoma.

LV: Hyphema and IOP spikes. In the long run loss of efficiency.

SS: Hyphema, transient IOP spike, stent obstruction, false passage, Descemet's detachment, stent malposition/ displacement, and infection are possible complications.

SD: Most encountered complication is hyphema but it is mostly self-limiting. Other rarer but known complications are DM detachment, IOP spike, inflammation with development of PAS, CME, choroidal detachment, & hypotony.

VRP: Complications associated with MIGS, are mostly infrequent and transient. Mispositioning and obstruction of micro-stents, hypotony and hyphema are the most reported complications. Ab-interno micro stents are subject to intraoperative mispositioning, which can result in luminal obstruction and decreased efficacy. Acutely elevated IOP has been observed.

NT: In what conditions is it to be removed, and how easy is it to remove a MIGS device?

GVR: Any device left in situ which reduces endothelial cell count is a safety hazard, can reduce vision and can cause permanent damage to ocular tissues. Such device needs to be removed. All devices can be removed easily provided the cornea is clear and the device has not dislodged from its location.

LV: I am not sure; I would prefer to watch.

SS: In cases of i-stent malposition causing complications like corneal edema, suprachoroidal migration, or choroidal detachment with persistent hypotony needs removal. I have not attempted any until now.

SD: Since i-stent is an inert implant made of titanium, if it gets lost in TM, no reports of any adverse events have been reported. Intra operatively, if i-stent is not properly positioned in TM, it can be immediately re-grasped, taken out on the cornea and repositioned again on TM & the same can be done by the inserter or micro forceps.

VRP: Malposition of a MIGS device may warrant a removal; however, if detected intra-operatively, stents can be easily extracted and reloaded on the injector devices and repositioned instantaneously.

NT: How many MIGS devices can be inserted at a time?

GVR: Some devices require to be implanted in pairs, like the Hydrus implant and the recommended number is three devices for i-Stent. For MIGS plus procedure like the Xen Gel Shunt and Innfocus shunt it is one device per procedure. Procedure based angular MIGS like Trabectome, GATT, Bang and Kahook Dual Blade require equipment to perform the procedure and no device is left in situ.

LV: It depends what is offered for patient. In case of i-stent better to use two.

SS: I have done only single one till now.

SD: One, two or three, I Stents can be implanted based on the severity of glaucoma. A combined procedure of goniotomy along with i-stent can also be performed.

VRP: Only i-Stent (generation 1 or G1) and i-Stent Inject (generation 2 or G2) MIGS devices are available in India. G1 is a 1mm non-ferromagnetic titanium device and comes pre-loaded as a single device. G2 on the other hand is much smaller

(0.3mm) and two such comes pre-loaded in the injecting device. As each need to be placed in the nasal-infero-nasal quadrant at least 2 clock hours apart, up to 3 of G1 or G2 can be implanted.

NT: How affordable are MIGS for a general Indian patient belonging to all tier cities?

GVR: Implantable MIGS devices available in India are expensive and of modest efficacy. The cost to benefit ratio is very poor. Procedure based MIGS device are easy to perform with less additional cost as compared to the former. It is important for us to understand that many glaucoma patients will be unwilling to undergo a surgical procedure for progressive mild glaucoma while medications are available easily.

LV: Standard procedures are expensive and not affordable for all. Some of the health insurance companies cover these procedures but not all. In general people are willing to spend on their health care, with good discussion we can help them decide. It is important to remember we should provide clear possible outcomes and limitations to our patients. Same way we should choose correct patients for the procedure.

SS: i-Stent and KDB are expensive. Alternative procedures like GATT and BANG are affordable.

SD: As per India Human Development Survey, an average Indian household's monthly income is Rs. 31,725. Based on this, I stent & KDB along with cataract surgery might be out of reach for an average Indian household. But more affordable options like GATT, BANG can be considered in patients where cost is a factor.

VRP: MIGS procedures that are available in India have a cost spectrum – on the one hand Bent Ab-interno BANG and suture GATT are cost-effective options. On the other there are procedures that may be more expensive like KDB Glide, ECP, Trabectome, i-Stent and i-Stent Inject.

NT: How has MIGS transformed outcomes for patients as well as surgeons?

GVR: MIGS is mixed bag for patients and surgeons. Generally, the conjunctiva sparing nature of MIGS is a boon which the glaucoma surgeon knows but translating it to the patient will require plenty of chair time.

LV: Able to eliminate or reduce medications when done with cataract surgery in eyes with mild to moderate open angle glaucoma. For surgeons it offers more options in treatment protocols.

SS: MIGS are a great addition to the existing techniques, has opened avenues to help control IOP in several ways and they are here to stay. They also have improved safety. However, long term IOP control and if any complications must be evaluated and looked for. Several MIGS procedures can be combined with cataract surgery which is an advantage.

SD: As far as outcomes are concerned, patients have shorter recovery time, better quality of life, less need for re surgery or return to OR in immediate post op period to handle post op complications. For a surgeon, MIGS have shorter surgical time & more predictable results with less complications in immediate post operative period.

VRP: MIGS are very patient-centric procedures due to shorter surgical procedure which is without any extra incisions or suturing, lesser post-operative visits, rapid recovery (akin to phacoemulsification). MIGS helps to eliminate or reduce AGM and improves compliance and adherence to therapy. Both these factors positively impact on Quality of Life. Furthermore, it helps in all those eyes where OSD or allergic reactions are a major concern – patients are well rid of their watery, red, irritable eyes.

NT: What are the challenges for MIGS in India?

GVR: Cost of the implants, efficacy of the procedure, and trained medical personal for identifying early progression (where MIGS are

useful) and performing MIGS are the current challenges.

LV: Major challenge for India and other low economic countries is the cost. The standard devices tested and approved are expensive, multinational companies should keep separate pricing for these countries. Alternate low-cost methods used in the country is not an ideal substitute, like to offer the best to our patients.

SS: Training and learning the correct technique, choosing the appropriate technique, high cost of some of the devices, and lack of knowledge on long term results.

SD: MIGS devices and procedures are different from traditional surgeries, and therefore may present a considerable learning curve. MIGS requires technical abilities which may be challenging, such as familiarity with using intraoperative gonioscope, accurate identification of angle structures and anatomy, and proper visualization and demand expertise. Cost of the devices is another big challenge.

VRP: There are currently multiple challenges to acceptability of MIGS in India; the foremost is the reluctance to accept change but cost and affordability is conveniently frequently cited as the biggest barrier. Successful implantation of a MIGS device or execution of a MIGS procedure demands a completely new set of skills. Lack of data in Indian eyes is another challenge that needs to be addressed, and limited availability of devices and procedures.


NT: Thank you very much, all of you, for sharing your opinions, expertise, and suggestions.

Congratulations Dr R. Ramakrishna



We congratulate Dr R. Ramakrishna, Senior Medical Consultant, Arvind Eye Hospital, Tirunelveli, for receiving the prestigious Prof. NN Sood Award from the Glaucoma Society of India and the Life-time Achievement Award from the Tamil Nadu Ophthalmological Society.

Glaucoma crossroads!!



Across

4. Hands free wide view direct gonioscopes, not manufactured by Apple Inc.
5. Lens with a handle, used for intra operative gonioscopy
7. Modern luminal trabeculotomy
10. Crescent shaped micro-stent with three windows and an inlet
11. Hydrophilic tube composed of porcine cross-linked gel

Down

1. Talk of the glaucoma town
2. Cost effective hands free direct gonioscopes
3. For electrocauter ab interno trabeculotomy
6. Suprachoroidal shunt, now withdrawn
8. First FDA-approved minimally invasive implantable device
9. The blade with a ramp

Compiled by Dr Purvi Bhagat

Dr Purvi Bhagat is Professor & Head of Glaucoma Services at M & J Western Regional Institute of Ophthalmology B. J. Medical College Ahmedabad, Gujarat. Glaucoma crossroads of this issue of the GSI Newsletter focusses on MIGS. Go ahead, and use your intent & knowledge to solve it.

Mail your entries to gsinewseditor@gmail.com. The first three correct entries will feature in the next issue of the e-newsletter.



32nd Annual Conference of Glaucoma Society of India



Hyatt Regency Pune
Oct 6-8, 2023

SAVE THE DATE



**SPECIAL
SUPER SAVER**
rates for registration

**SPECIAL RATES
FOR VENUE
ACCOMODATION**

INVITATION

Welcome to Pune, the educational, IT, cultural capital, and a bustling metropolis of Maharashtra. Come and enjoy the academic feast, **GlaucoPune 2023, the 32nd Annual Conference of Glaucoma Society of India, to be held from 6-8 October, 2023 at Hotel Hyatt Regency**. The city has excellent connectivity with all major cities in India.

Pune is privileged to host this prestigious national conference of glaucoma specialists from across the country for the first time. We eagerly look forward to welcoming you to an excellent academic and cultural experience you will cherish for many years.

GSI conferences provide a unique opportunity to learn from top glaucoma experts and to present your work too. It is an opportunity to catch up with former friends and colleagues and make new friends. This academic interaction will make us all wiser in managing our Glaucoma patients more efficiently.

Pune offers lots to explore, from the varied culinary spread to some special tourist destinations. **GlaucoPune** will be an ideal chance to indulge in academics and as well as fun.

We shall leave no stone unturned to make this conference truly special and invite you to the cultural capital of one of the most vibrant states of India.



Dr Barun Kumar Nayak
President



Prof Manav Deep Singh
Hony. Gen Secretary



Dr Medha Prabhudesai
Organising Chairman



Dr Mandar Paranjpe
Organising Secretary